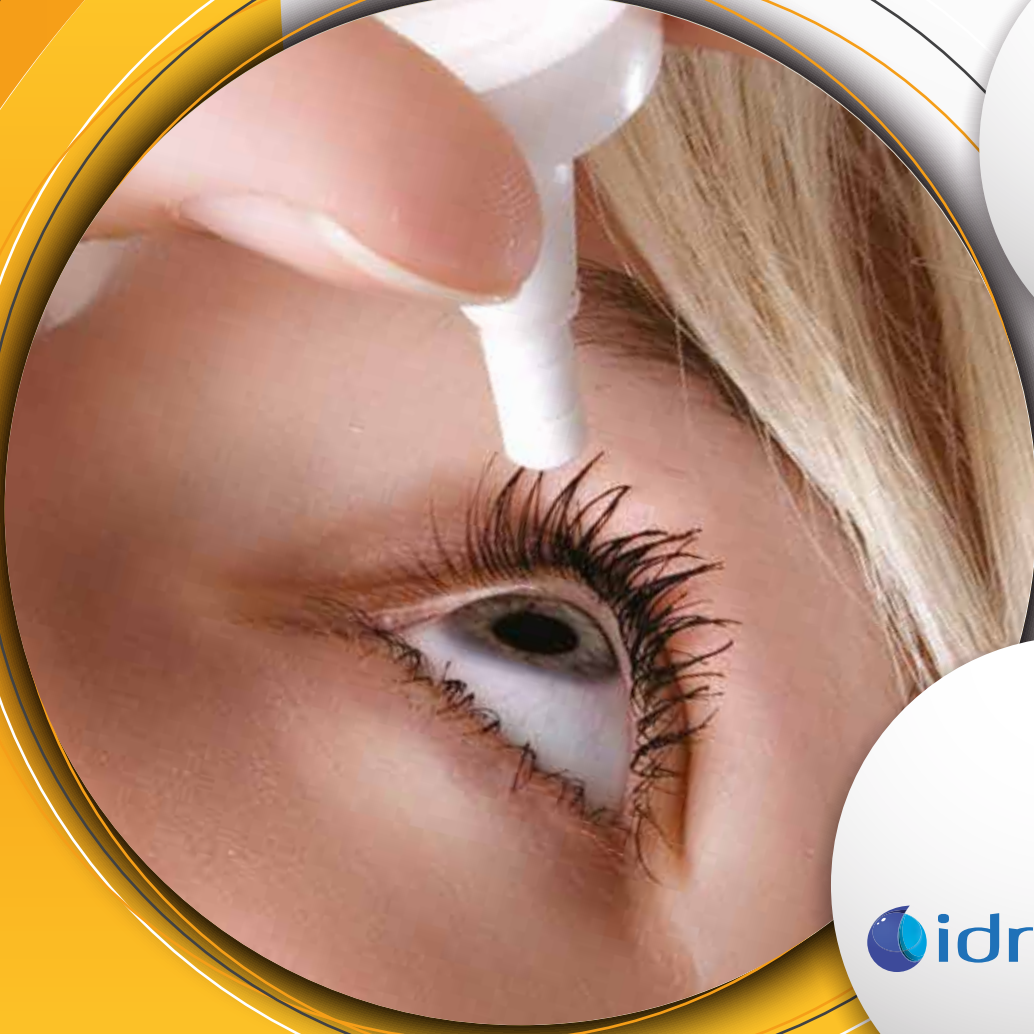

DEDICATED DRY EYE CLINIC

It is an integrated diagnostic platform easy to use.
Connection to the most common telemedicine systems.

uni en iso 9001:2015 Nr. 8631/0
uni cei en iso 13485:2012 Nr. 8632/0



 O.S.O.



 idra

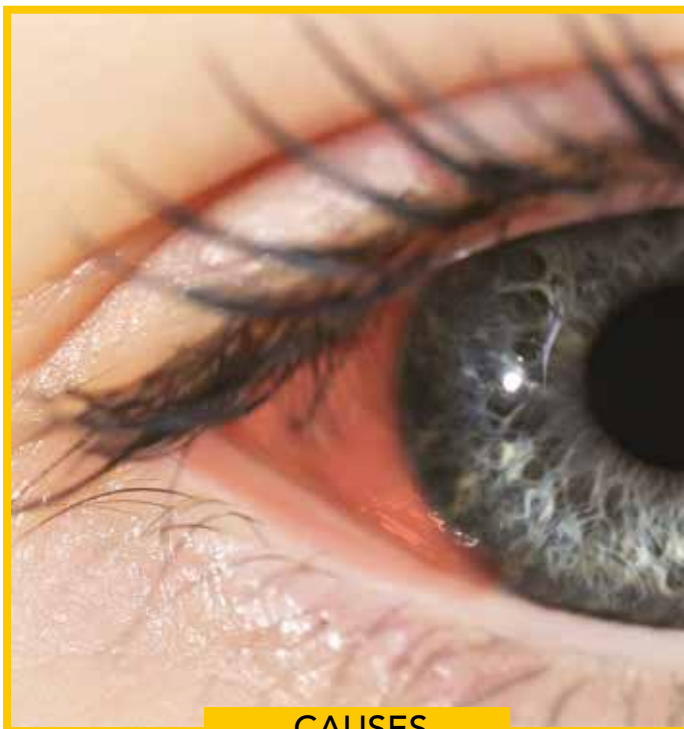HOW ARE DRY EYES DIAGNOSED?

OCULAR SURFACE WORKUP WITH AUTOMATED NON-INVASIVE MEASUREMENTS FOR THE DIAGNOSIS OF MEIBOMIAN GLAND DYSFUNCTION

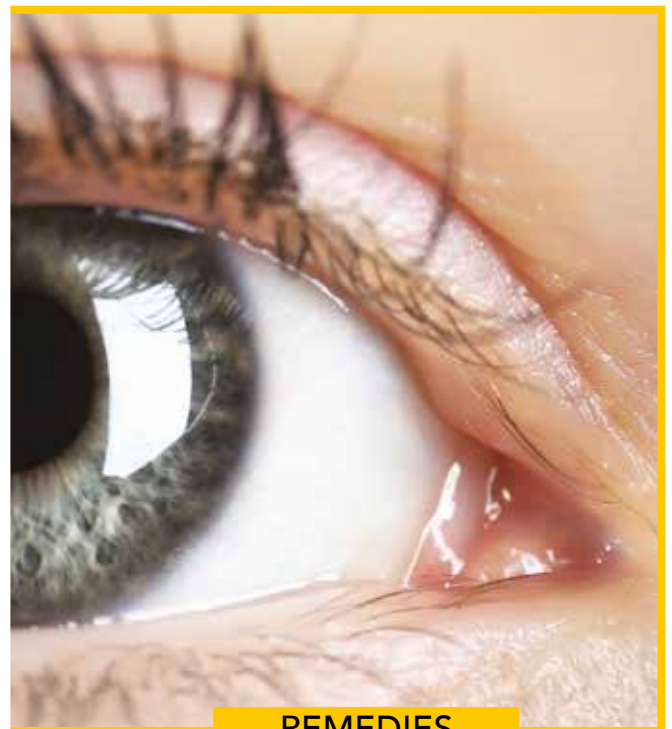
Dry eyes can be diagnosed through a comprehensive eye examination.

Testing, with emphasis on the evaluation of the quantity and quality of tears produced by the eyes, may include:

- Patient history to determine the patient's symptoms and to note any general health problems, medications or environmental factors that may be contributing to the dry eye problem.
- External examination of the eye, including lid structure and blink dynamics.
- Evaluation of the eyelids and cornea using bright light and magnification.
- Measurement of the quantity and quality of tears for any abnormalities. Special dyes may be put in the eyes to better observe tear flow and to highlight any changes to the outer surface of the eye caused by insufficient tears.



CAUSES



REMEDIES

- The natural aging process, especially menopause
- Diseases that affect your ability to make tears, like Sjogren's syndrome, rheumatoid arthritis, and collagen vascular diseases
- Conjunctivitis
- Environmental conditions. Exposure to smoke, wind and dry climates can increase tear evaporation resulting in dry eye symptoms. Failure to blink regularly
- Problems that don't allow your eyelids to close in the right way
- Treatment with Cataract surgery
- Treatment with Medications including antihistamines, decongestants, blood pressure medications and antidepressants, can reduce tear production
- Other factors. Long-term use of contact lenses can be a factor in the development of dry eyes
- Refractive eye surgeries, such as LASIK, can decrease tear production and contribute to dry eyes.

- Treatment with Artificial tears
- Steroid Eye drops
- Restasis
- Xiidra
- Lacrisert
- Punctal plugs
- Intense Pulsed Light therapy has been used with positive results if there are oil gland problems
- Use of a cool mist humidifier to add moisture to the air
- Drink water throughout the day to stay hydrated
- Warming of the Meibomian Glands
- Specific diets.

Ocular Surface Workup With Automated Noninvasive Measurements for the Diagnosis of Meibomian Gland Dysfunction with SBM Sistemi device

INTRODUCTION THERAPEUTIC DIAGNOSTIC

Dry eye disease was recently redefined as a "multifactorial disease of the ocular surface characterized by a loss of homeostasis of the tear film, and accompanied by ocular symptoms, in which tear film instability and hyperosmolarity, ocular surface inflammation and damage, and neurosensory abnormalities play etiological roles."¹ Meibomian gland dysfunction (MGD) represents the leading cause of evaporative dry eye, the most common subtype of dry eye².

MGD is characterized by hyperkeratinization of the meibomian gland ductal epithelium, leading to obstruction and plugging of the gland orifice. Moreover, quantitative and qualitative changes in the meibum lipid composition lead to increased viscosity and reduced gland outflow onto the tear film. The stasis of meibum inside the gland promotes proliferation of bacteria, producing lipases and esterases that increase the viscosity and melting temperature of the meibum, thus setting up a vicious spiral. Hyposecretion of meibomian lipids causes thinning of the tear film lipid layer, with consequent tear film instability, increased evaporation rate, and dry eye onset.

MATERIALS AND METHODS

Study Population

This cross-sectional study was conducted at Carones Ophthalmology Center (Milan, Italy) between September 2016 and July 2017. The study was performed in accordance with the principles of the Declaration of Helsinki and was approved by the local institutional review board. Written informed consent was obtained from all subjects before the examination.

DISCUSSION

The accurate diagnosis and classification of dry eye are complicated by the heterogeneous nature of the disease and the variability of signs and symptoms. Various diagnostic assessments have been proposed to qualitatively and quantitatively characterize the entire ocular surface system. However, to date, no universally accepted diagnostic workup for the diagnosis of MGD has been established. Several tests used routinely in daily practice require direct contact with the eye and/or the use of eye drops. The resulting alteration of the tear film volume and composition may not only influence the measured variable itself but also have disruptive effects on the results of subsequent tests. In addition, some tests require the clinician's judgment to reach a score and, therefore, are open to significant observer bias. Furthermore, measurements obtained using traditional tests are often affected by low values of repeatability and reproducibility. Recently, new automated noninvasive quantitative tests have been developed to overcome these drawbacks. They include, among others, tear film interferometry, noncontact meibo-

graphy, and tear osmolarity. In particular, interferometry is a technique that studies the surface reflection pattern and dynamics of the lipid layer of the tear film, thus allowing the measurement of the tear film stability and the thickness of the lipid layer. The measurement of BUT with a noninvasive technique eliminates the disturbance on the tear film caused by instillation of fluorescein dye. Meibography allows in vivo observation of the meibomian gland morphology; the gland structural changes may be graded with different scoring systems. In addition, new digital software allows automated calculation of the total meibomian gland area in the lower and upper eyelids. Tear film osmolarity has been reported as the single best metric to diagnose and grade severity of dry eye. However, some authors questioned its clinical utility because of the high variability of measurements and the lack of correlation with dry eye signs and symptoms.

IN CONCLUSION

The automated non-invasive ocular surface diagnostic workup used in the present study may represent a promising diagnostic tool for MGD diagnosis. Although no single test has proved able to reach the diagnosis with sufficient accuracy, MGD may be strongly suspected when one between NIBUT and meibography combined in parallel is abnormal. Therefore, in case of positivity of either NIBUT or MGL, subsequent qualitative clinical tests should be performed to achieve a reliable diagnosis and a more precise characterization of MGD.

Giuseppe Giannaccare, MD, PhD,^{1*} Luca Vigo, MD,^{2*}
Marco Pellegrini, MD,¹ Stefano Sebastiani, MD,¹
Francesco Carones, MD²

1 Ophthalmology Unit, DIMES, S.Orsola-Malpighi University Hospital, University of Bologna, Bologna, Italy

2 Carones Ophthalmology Center, Milan, Italy

* The Authors contributed equally and should be considered co-first authors



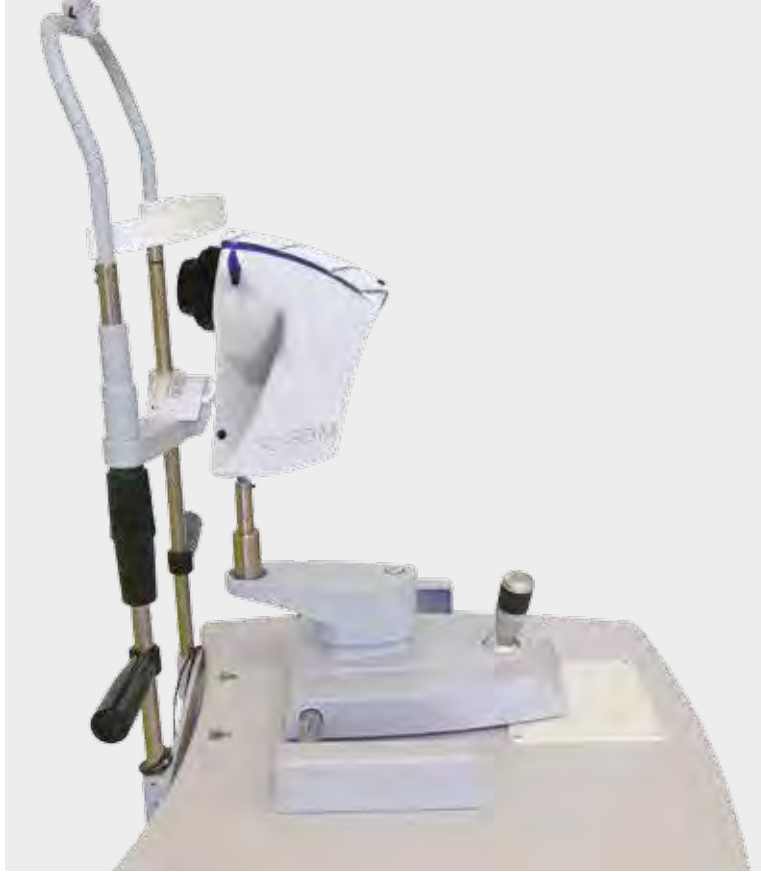The importance of images in educating patients and encouraging compliance cannot be overstated. A picture is truly worth a thousand words. When you tell a patient he has advanced MGD and paint a verbal picture of the prognosis if left untreated it is likely to be ignored. If you are able to demonstrate the problem pictorially it has a greater impact. Using SBM Sistemi the Doctor can show the patient library photos of moderate and severe MGD to compare with his personal photos. The photos will then be kept with the patient records for future reference and comparison.



INTEGRATED SYSTEM FOR THE ANALYSIS OF THE OCULAR SURFACE

The instrument is mounted in the slitlamp tonometer hole. It is designed to do all tearfilm tests, from the quality of tears to analysis of the meibomian glands using international grading scales.

In addition the SBM Device allows a clinician to check different parameters such as PLR in more detail.



TECHNICAL DATA

IMAGE RESOLUTION	5 MP
ACQUISITION MODE	Multi shot, video
FOCUS	Autofocus, manual focus
ISO MANAGEMENT	Variable
CONES	Main cone and Placid cone
CAMERA	Colored, sensitive to infrared (NIR), yellow-filtered
LIGHT SOURCE	Infrared LED – Blue and white Led

MINIMUM HARDWARE REQUIREMENTS:

- Intel® Pentium® Dual Core 2.00 Ghz
- SSD Hard Drive
- 4 GB RAM
- Screen resolution: 1600x900
- 1 available usb 3.0 port
- 1 other available usb port
- Microsoft® Windows® 7, 8, 10 Professional (Pro)

Considering the high quality of the videos, for optimal video recording and playback we suggest:

- Intel® Core™ i7
- 8GB RAM

IDRA registration number at the Ministry: 1705624/R

Invented and developed 100% in Italy

Medical instrument in CLASS I registered to the Ministry of Health

Medical electrical equipment CLASS I complies with the norm En. 60601-1.

The technical features of the instrument and its accessories can be improved in any time and without notice.

To obtain an updated description we suggest to visit the website www.sbmsistemi.com

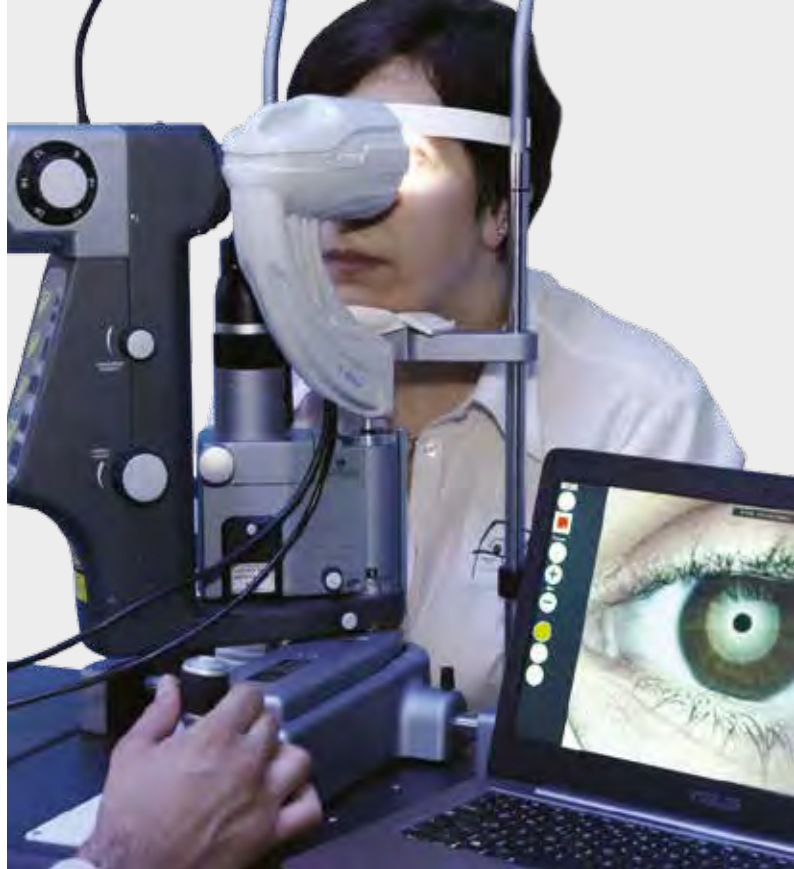

The importance of images in educating patients and encouraging compliance cannot be overstated. A picture is truly worth a thousand words. When you tell a patient he has advanced MGD and paint a verbal picture of the prognosis if left untreated it is likely to be ignored. If you are able to demonstrate the problem pictorially it has a greater impact. Using SBM Sistemi the Doctor can show the patient library photos of moderate and severe MGD to compare with his personal photos. The photos will then be kept with the patient records for future reference and comparison.



INTEGRATED SYSTEM FOR THE ANALYSIS OF THE OCULAR SURFACE

The instrument is mounted in the slitlamp tonometer hole. It is designed to do all tearfilm tests, from the quality of tears to analysis of the meibomian glands using international grading scales.



TECHNICAL DATA

IMAGE RESOLUTION	5 MP
ACQUISITION MODE	Multi shot, video
FOCUS	Autofocus, manual focus
ISO MANAGEMENT	Variable
GRIDS	Placid disc, NIBUT grid
CAMERA	Colored, sensitive to infrared (NIR)
LIGHT SOURCE	Infrared LED – Blue and white Led

MINIMUM HARDWARE REQUIREMENTS:

- Intel® Pentium® Dual Core 2.00 Ghz
- SSD Hard Drive
- 4 GB RAM
- Screen resolution: 1600x900
- 1 available usb 3.0 port
- 1 other available usb port
- Microsoft® Windows® 7, 8, 10 Professional (Pro)

Considering the high quality of the videos, for optimal video recording and playback we suggest:

- Intel® Core™ i7
- 8GB RAM

I.C.P. OSA registration number at the Ministry: 1556084/R

Invented and developed 100% in Italy

Medical instrument in CLASS I registered to the Ministry of Health

Medical electrical equipment CLASS I complies with the norm En. 60601-1.

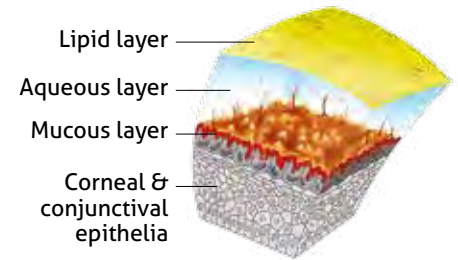
The technical features of the instrument and its accessories can be improved in any time and without notice.

To obtain an updated description we suggest to visit the website www.sbmsistemi.com

THERAPEUTIC DIAGNOSTIC


FUNCTIONS

The SBM Device is the new instrument of individual analysis of tear film that allows to do a quick detailed structural research of the tear composition. Research on all the layers: Lipid, Aqueous, Mucin. Thanks to the SBM Device it is possible to identify the type of DED (Dry Eye Disease) and determine which layers can be treated with a specific treatment, in relation to the type of deficiency.



INTERFEROMETRY

The SBM Device can evaluate the quantity and the quality of the lipid component on the tear film. The device enlight the lipid layer and the pattern defined can be compared with the reference grading scale.



TEAR MENISCUS

The size of the tear meniscus formed on the eyelid borders provides useful information on the volume of produced tears. The tear meniscus can be examined considering its height, regularity and shape.



NIBUT

The stability of the mucin layer and the whole tear film is measured through BUT or NITBUT, by using grids that are projected onto the cornea you are able to evaluate manually or automatically the time when the tear break up occurs.



MEIBOGRAPHY

It images the morphology of the glands in order to diagnose any meibomian gland drop out which would lead to tear dysfunction. Meibography is the visualization of the glands through trans-illumination of the eyelid with infrared light.



BLEPHARITIS

This test helps in detection of blepharitis and Demodex, which can be performed on the outer surface of the eye and eyelids.



OCULAR REDNESS CLASSIFICATION

Once you have captured the image of the blood vessels of the conjunctiva it will be possible to compare them to the classification sheets of bulbar and limbal redness degree.



PUPILLOMETRY

Measurement of the pupil reaction to light with and without glare. Measurement mode: SCOTOPIC, MESOPIC, PHOTOPIC

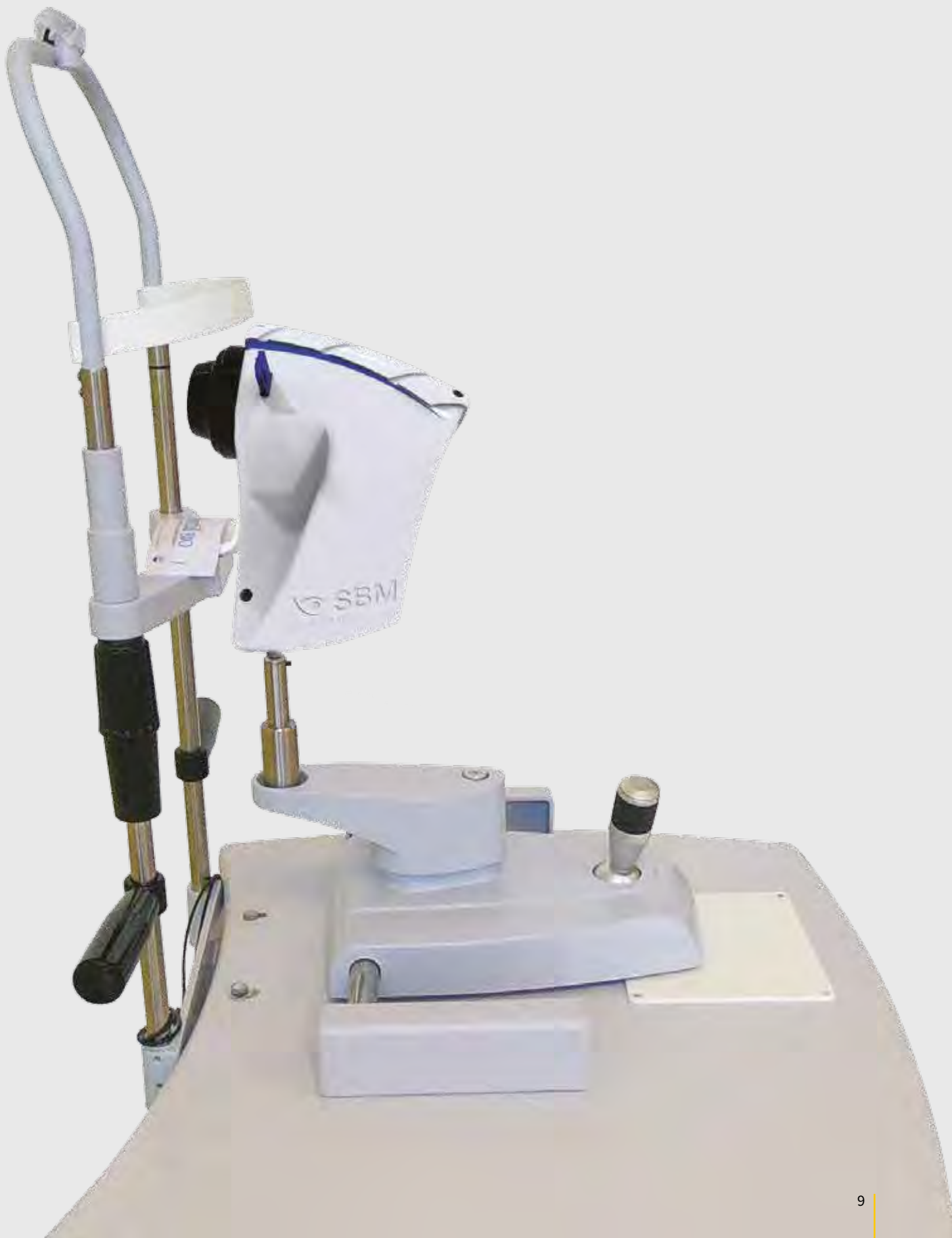

WHITE TO WHITE MEASUREMENT

Evaluation of corneal diameter from limbus to limbus (white-to-white distance, WTW).



GENERIC EXAM



AUTO INTERFEROMETRY

idra



Using the new SBM Sistemi "IDRA", interferometry get easy, is quick and automatic.

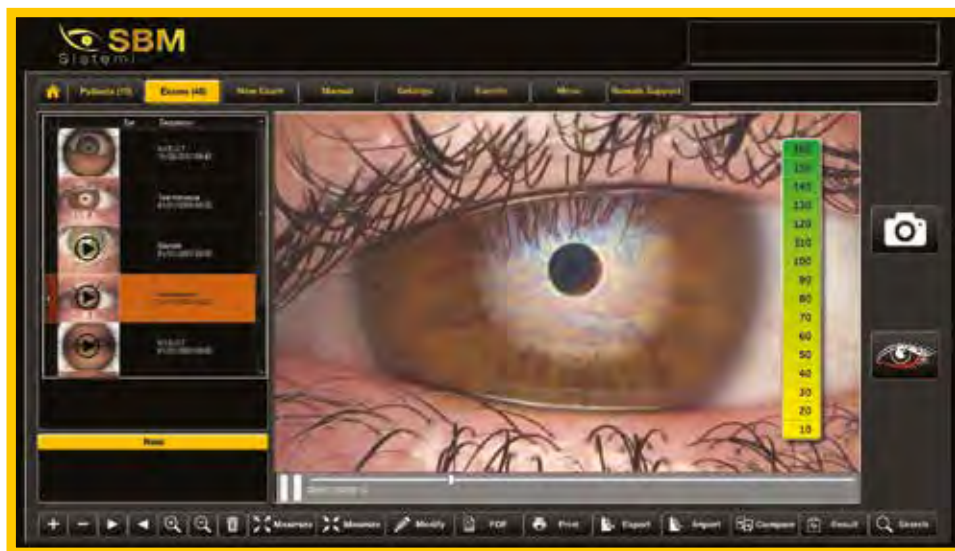
The software automatically detects the coloured lipids on the patient's eye and determines LLT (lipid layer thickness) using the international OD Guillon's study.

AUTO DETECTION OF:

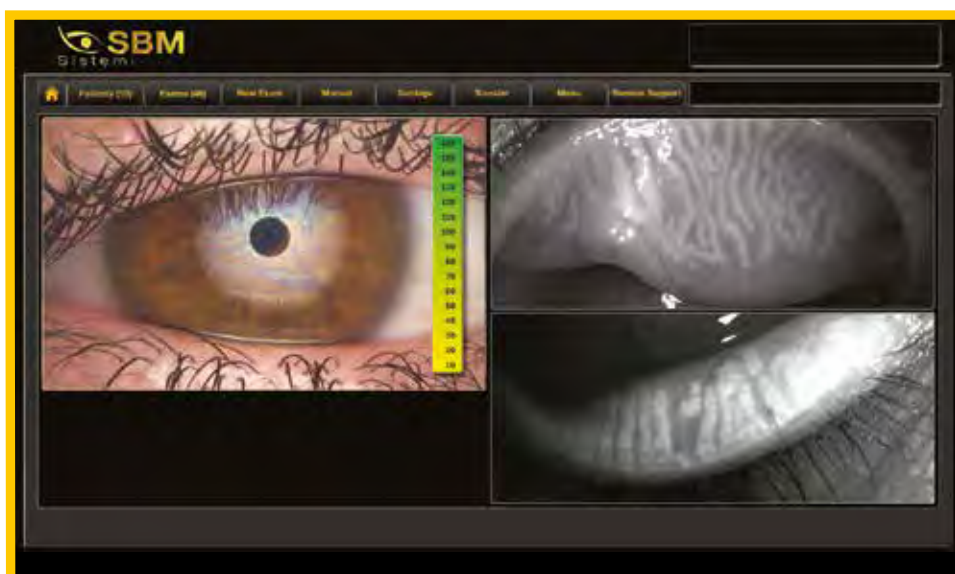
Maximum thickness of Lipid layer

Average Thickness

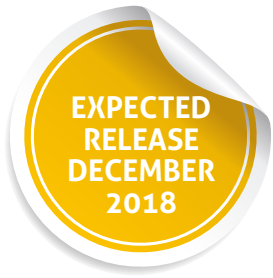blinking rate



VALUES ARE DISPLAYED ON A USER FRIENDLY GRADING SCALE THAT CAN BE USED TO EXPLAIN THE PATHOLOGY TO PATIENTS.



COMPARISON BETWEEN MG AND LLT TO UNDERSTAND FUNCTIONALITY OF MEIBOMIAN GLANDS BEFORE AND AFTER TREATMENTS.



IDRA ASSESSMENT

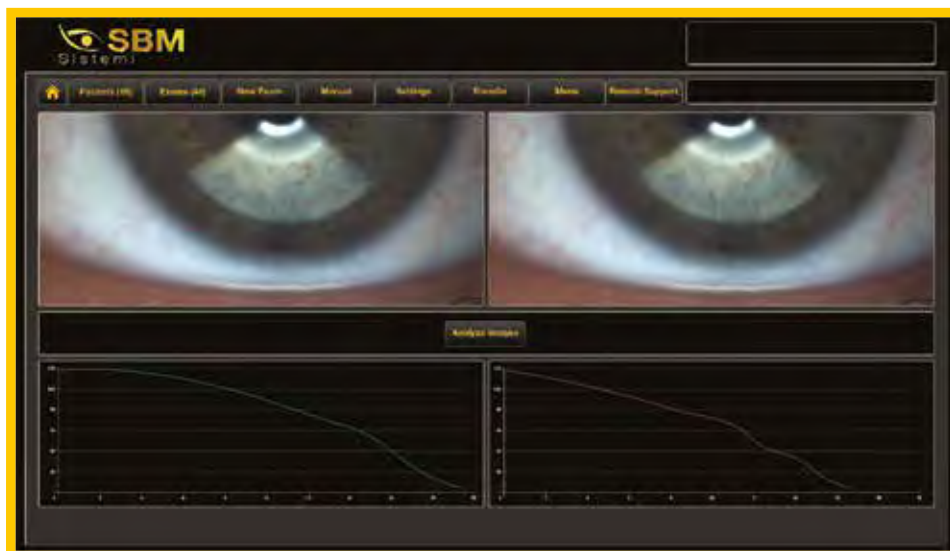
IDRA must be inserted in the support between slit lamp and biomicroscopy.

It's pin has been built in order to fit perfectly into the hole that you can see when the plate used for the tonometer is removed.

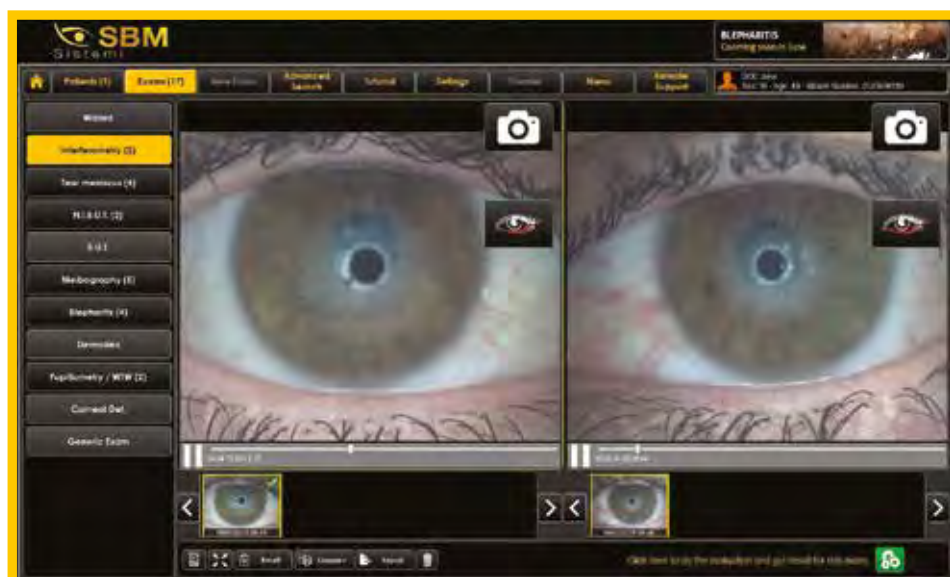
Sit the patient comfortably using the chin holder so the patient is still for the examination.

The device must be kept as close to the eye as possible without touching.

The closer the device is to the eye the broader the area lit by the instrument. The light reflected from the tear film can be observed as a white circular area that almost completely covers the cornea.



LIPID LAYER THICKNESS ON SAME EYE BEFORE AND AFTER TREATMENT.



VALUES ARE DISPLAYED ON A USER FRIENDLY GRADING SCALE THAT CAN BE USED TO EXPLAIN THE PATHOLOGY TO PATIENTS.

INTERFEROMETRY

idra



O.s.a.



The evaluation of the lipid layer is part of your overall Dry Eye Assessment.

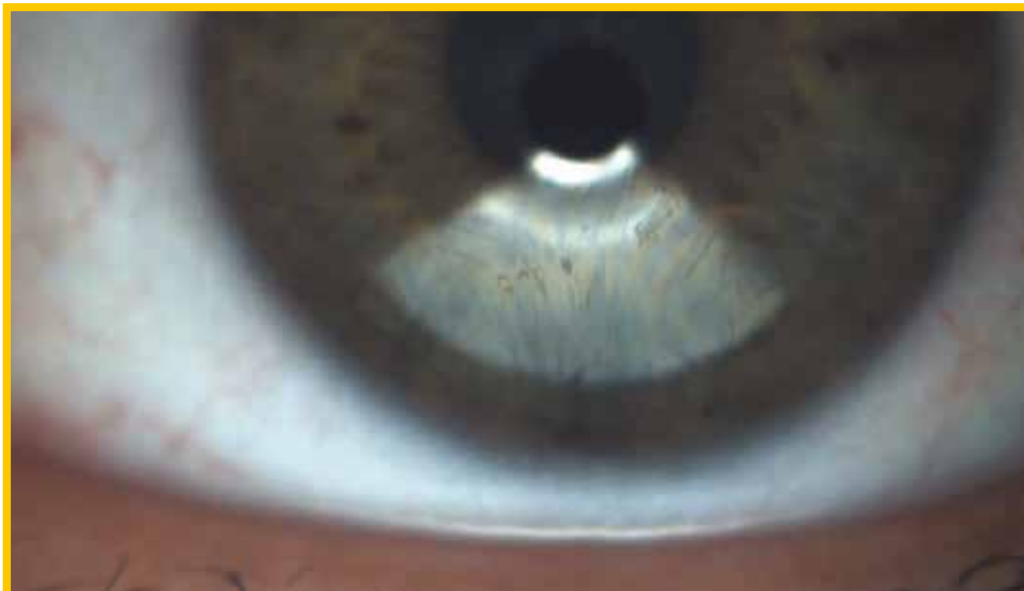
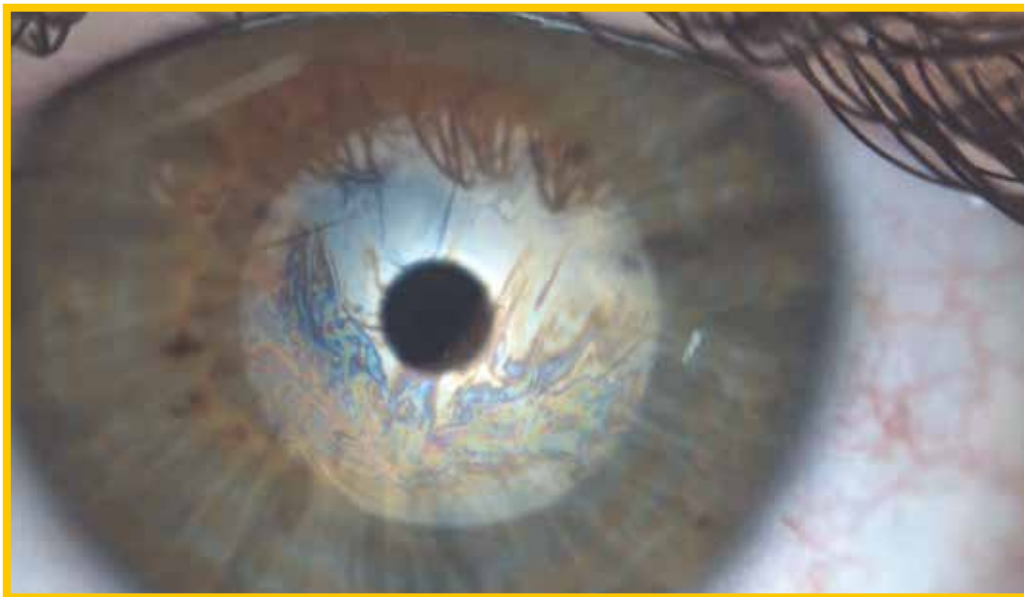
Knowing what is causing Dry Eye will help determine the best treatment option.

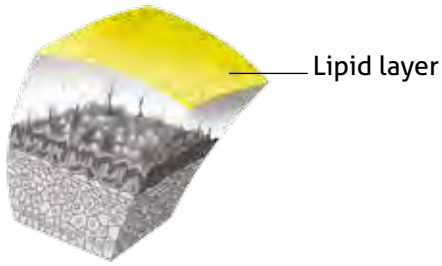
After your assessment is complete, the Optometrist will discuss your treatment options.

Using the device it is possible to do an interferometric analysis of the lipid layer in the tear film. The tear film plane must be focused, while the image of the bright circle must remain blurred. Depending on its thickness and regularity, the lipid layer may appear like any of the following: amorphous structure, marble appearance, wavy appearance, yellow, brown, blue or reddish interference fringes.

"When the tool shows a matt white pattern, it means that there are no lipids; if it shows a white and quick movement of the image, so the lipid layer is present and in a borderline condition; when the resulting image is full of colors, it means there are many lipids.

This exam is of fundamental importance, because most of the dry eye diseases are caused by an insufficiency of lipid layer quantity. In fact, aqueous layer evaporates without lipids and the eyes are more exposed to the risk of DED."





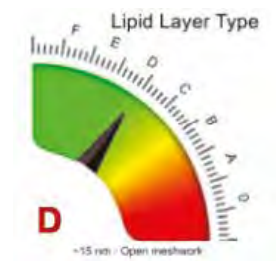
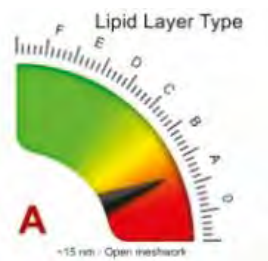
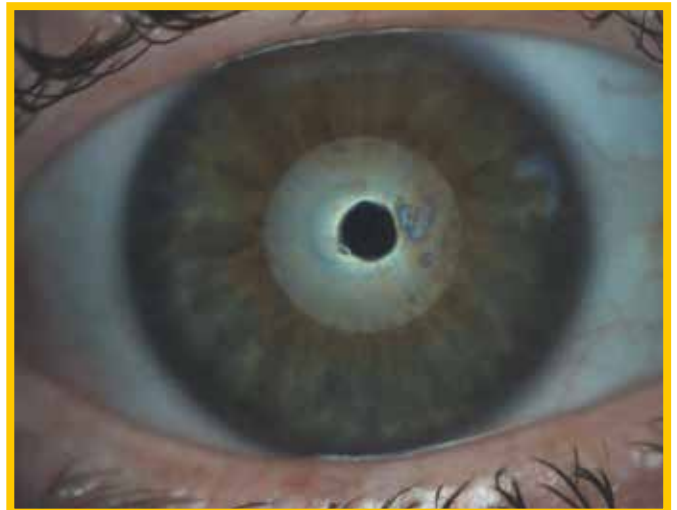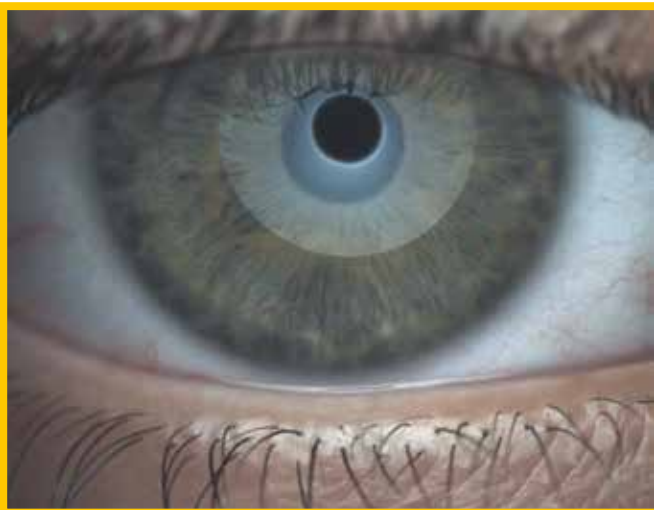Lipid pattern classification, incidence and clinical interpretation, adapted from Guillon & Guillon description incidence (%) estimated thickness (nm) appearance clinical. Observation of blinking frequency and completeness should also be considered - while listening to history and symptoms can be an ideal time to observe this.

A typical blink pattern can be observed as approximately one blink every five seconds, ie 11 blinks per minute. Incomplete blinking can often be observed in contact lens wearers, and frequent blinking may be a result of an attempt to maintain a relatively thin lipid layer.

LIPID LAYER ANALYSIS

The Lipid analysis was good for OD eye with values greater than >80nm

The Lipid analysis for OS was <30nm



LIPID LAYER THICKNESS

Presents lipid layer thickness measurements in an easy to understand color-coded map.

The identification is done through the international grading scale of Dr. Guillon

TEAR MENISCUS HEIGHT MEASUREMENT



Small tear volumes may result in dry eye symptoms, especially in aqueous tear deficiency (ATD). However, measuring the actual tear volume is difficult because the methods are invasive and irritative.

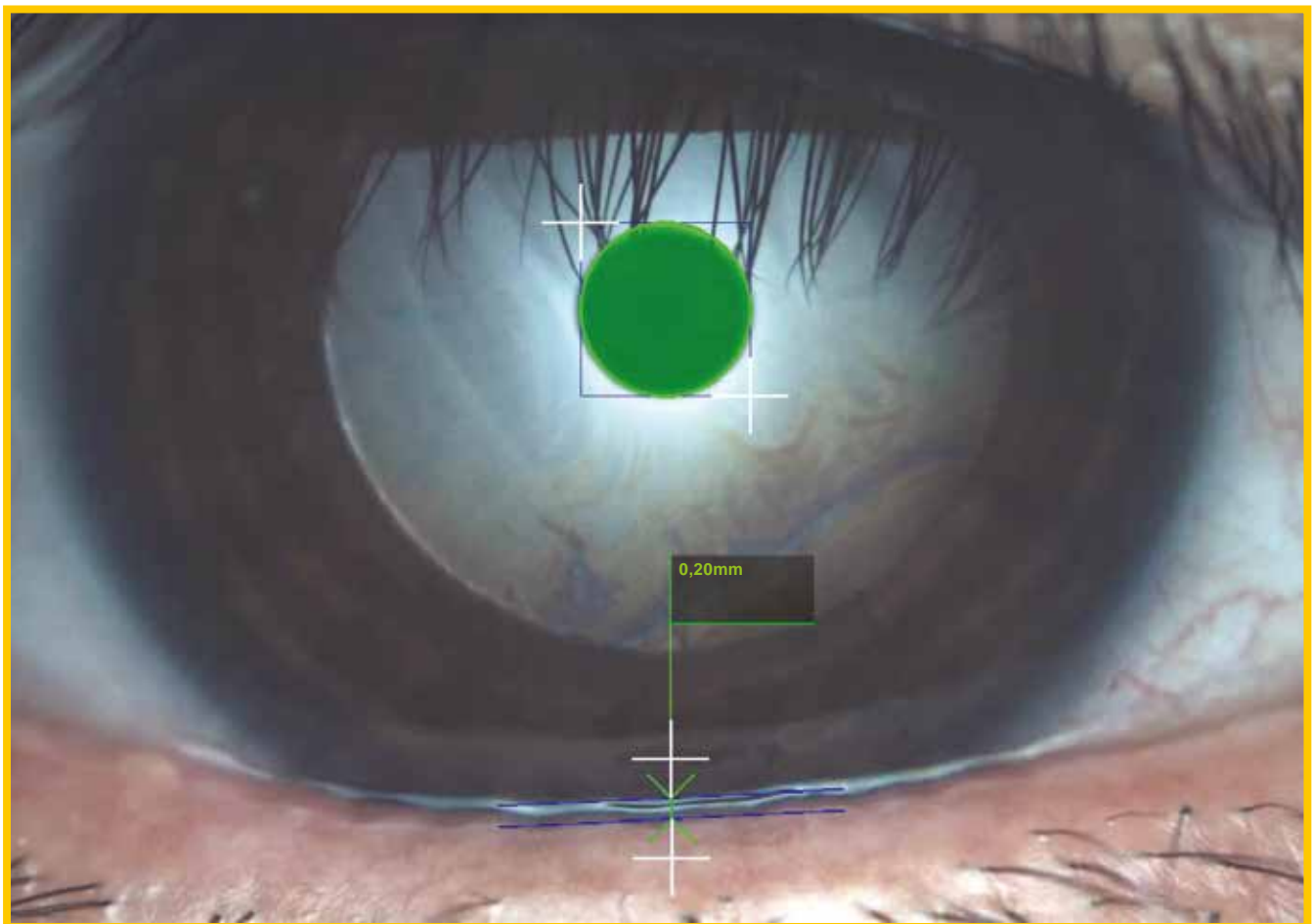
Reflex tear production can be induced, giving an overestimation of basal tear flow and volume. The sizes of the tear menisci are related to the tear secretion rate and tear stability, and they are good indicators of the overall tear volume.

The tear layer is a thin layer of liquid of about 8μ . It's thickness is variable but is at its maximum at the corneal level. It is composed of 98% water and for the remainder 2% protein and lipids and is uniformly distributed across the ocular surface by the opening and closing of the eye lid.

A stable tear film plays an important role in the quality of our vision. It also plays a key role by optimizing lid comfort by reducing friction, transport of different molecules and vital elements for the corneal epithelial health. Enzymes in the tear film are responsible for antibacterial defense and help clean other impurities.


The aqueous layer is evaluated through the non invasive "Tear Meniscus" test, classifying it in different categories and possible issues related to this.

The measurement (in mm) allows the direct evaluation of this layer quantity, and it is comparable to the Schirmer's Test with the difference that "Tear Meniscus" is without invasiveness and it does not take four minutes (only take a photo).



Evaluation of the tear film quantity.

With the various magnification tools you can measure the tear meniscus height and evaluate its characteristics along the lower lid margin. The result of this exam is comparable to the Schirmer's test one, with the difference that it is not invasive and lasts 3 seconds instead of several minutes.



The SBM Device is an excellent method of screening for dry-eye patients, to measure the upper and lower tear menisci in patients with aqueous tear deficiency (ATD) dry eye by the SBM Device and to determine the most effective meniscus variables for the diagnosis of dry eye. Normal tear volume is important for the maintenance of ocular surface physiology and ocular comfort.

The total tear volume is composed of the tear meniscus, which contains 75% to 90% of the tears the pre-ocular film; and the cul-de-sac. Small tear volumes may result in dry eye symptoms, especially in aqueous tear deficiency (ATD). However, measuring the actual tear volume is difficult because the methods are invasive and irritative.

Reflex tear production can be induced, giving an overestimation of basal tear flow and volume.

QUESTIONNAIRE

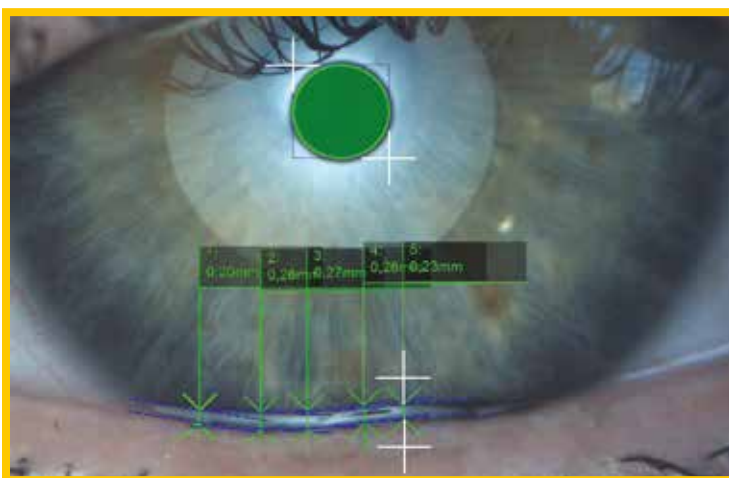
To have a complete evaluation of the presence or not of Dry Eye condition, the software allows you to do a Questionnaire related to the subjective symptoms of the patient.

In this way, it is easier to understand if there is dry eye pathology or if it's symptomless.



The sizes of the tear menisci are related to the tear secretion rate and tear stability, and they are good indicators of the overall tear volume. Estimates of menisci size and volume have been attempted by photographic and interferometry methods. These methods allow the simultaneous imaging of both the upper and lower menisci.

Recent advances and associated software have enabled the simultaneous imaging of both menisci, and real-time changes have been reported. derived quantitative measurement of tear meniscus variables enable this noninvasive modality as a potential diagnostic tool of dry eye.



THANK TO THIS VERSION, YOU WILL HAVE THE POSSIBILITY TO ACQUIRE UP TO 5 MEASURING POINTS

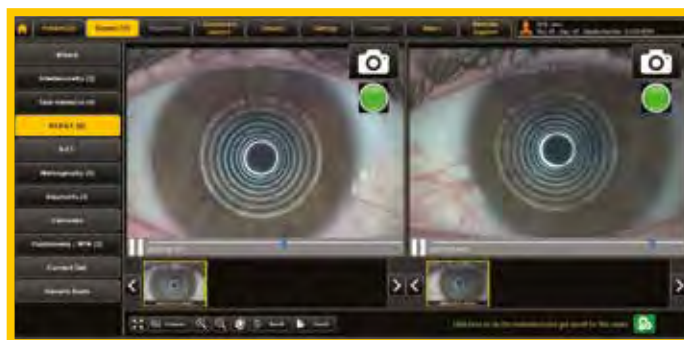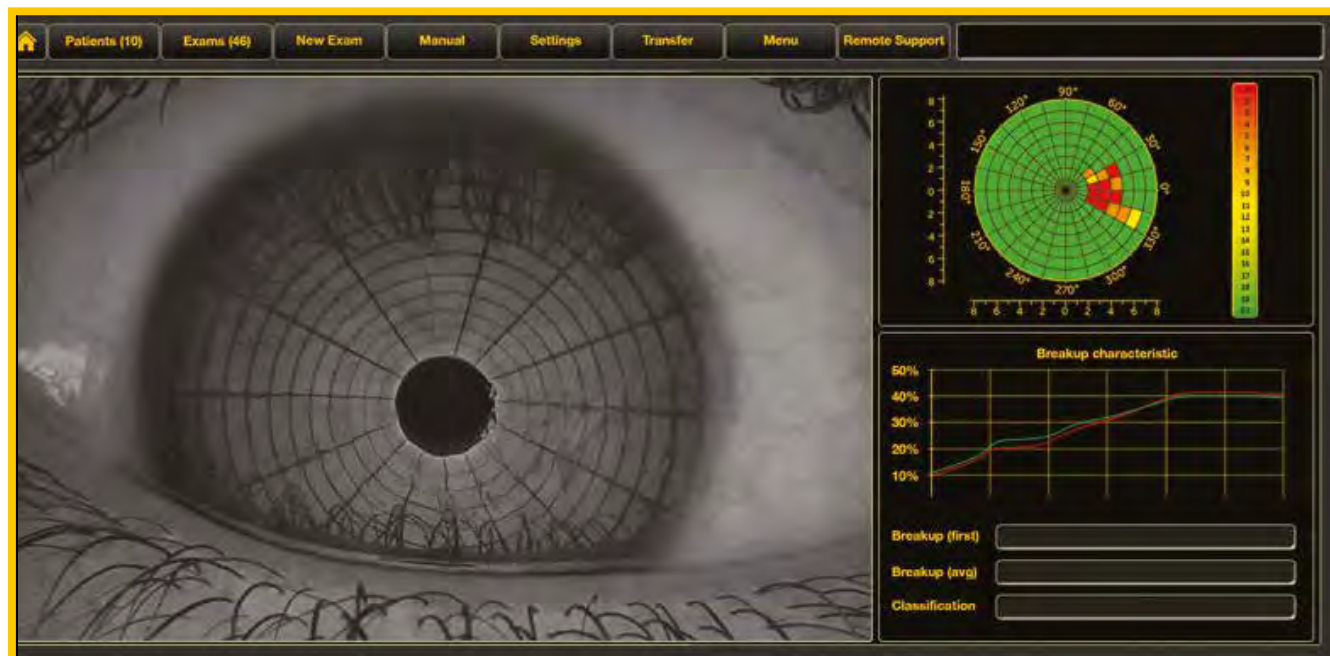AUTO-NIBUT




The SBM Device allows to evaluate stability and regularity of the tear film, using non-invasive break up time measurement (NIBUT). In fact, grids can be inserted inside the SBM Device's internal cylinder to project structured images on the tear film surface.

The non-invasive break up time is the measurement, in seconds, of the time between the last complete blink and the appearance of the first discontinuity on the tear film.

With the SBM Device tool, the Doctor can choose between manual or auto NIBUT: the first one requires the direct participation of the specialist; the second one is completely charged to the software.





Mucin Layer

BLINK RATE



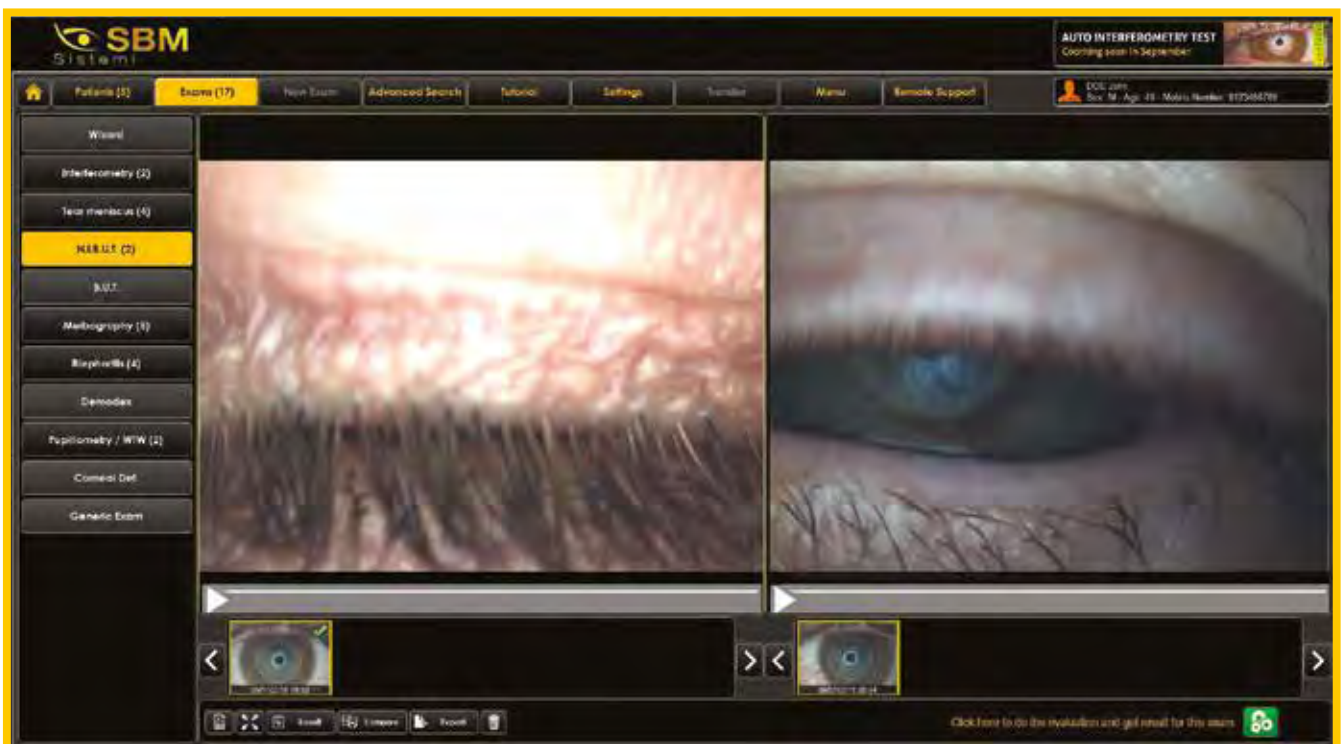
A healthy human would be expected to show periodic blinks, making a brief closure of the eyelids. Most blinks are spontaneous, occurring regularly with no external stimulus. However a reflex blink can occur in response to external stimuli such as a bright light, a sudden loud noise, or an object approaching toward the eyes. A voluntary or forced blink is another type of blink in which the person deliberately closes the eyes and the lower eyelid raises to meet the upper eyelid.

A complete blink, in which the upper eyelid touches the lower eyelid, contributes to the health of ocular surface by providing a fresh layer of tears as well as maintaining optical integrity by providing a smooth tear film over the cornea.

The rate of blinking and its completeness vary depending on the task undertaken during blink assessment, the direction of gaze, the emotional state of the subjects and the method under which the blink was measured. It is also well known that wearing contact lenses (both rigid and soft lenses) can induce significant changes in blink rate and completeness.

It is been established that efficient blinking plays an important role in ocular surface health during contact lens wear and for improving contact lens performance and comfort.

Inefficient blinking during contact lens wear may be related to a low blink rate or incomplete blinking and can often be a reason for dry eye symptoms or ocular surface staining.



MEIBOGRAPHY

idra



O.s.a.



Meibomian glands play a significant role in tear production by contributing lipids to the superficial tear film. Dysfunction of the meibomian glands destabilizes tears resulting in evaporative dry eye.

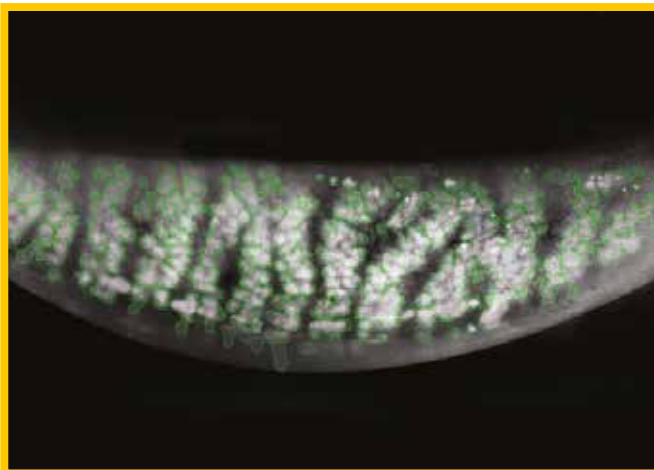
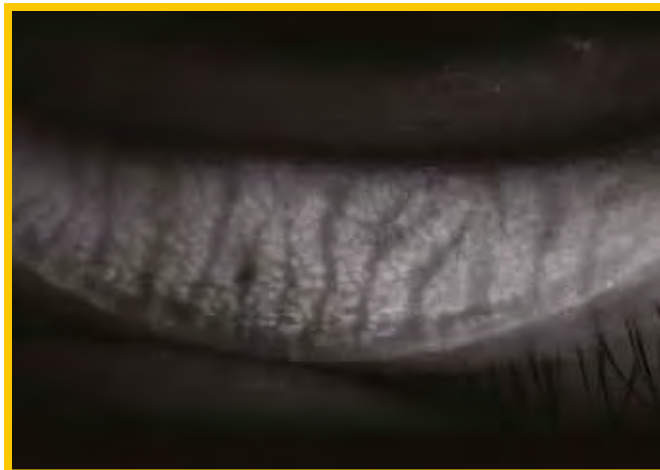
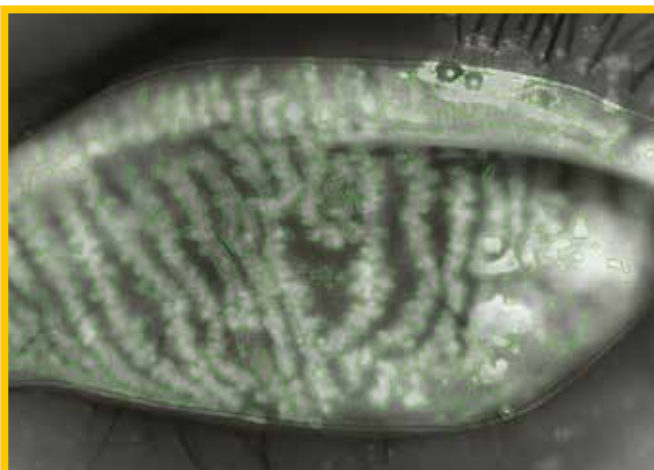The posterior lamella of the eyelid hosts a fleet of meibomian glands situated between the palpebral conjunctiva and tarsal plate. A normal meibomian gland is approximately linear and 3–4 mm in length, traversing the posterior eyelid perpendicularly from the lid margin to the opposite edge of the tarsus.

Closer inspection of a meibomian gland demonstrates a tubulo-acinar architecture with saccular arrangements of acini and a ductal system that communicates with orifices near the mucocutaneous junction of the eyelid.

Glandular acini contain clusters of modified sebaceous cells called meibocytes.

The functional unit of a meibomian gland is the meibocyte which synthesizes and secretes lipids (meibum) into the precorneal tear film. Meibum permeates the tear surface where it serves several important functions. It prevents tear evaporation and thus desiccation of the ocular surface; it acts as a physical and hydrophobic barrier to the inward movement of environmental and organic agents; and it lubricates the ocular surface to prevent irritation while promoting a clear ocular image. Consequently, tear physiology is dependent upon the proper functioning of the meibomian glands

MEIBOMIAN GLAND AUTO DETECTION ON BOTH LIDS



THE SBM DEVICE CAN, IN A GUIDED WAY, DETECT THE LENGTH AND WIDTH OF MEIBOMIAN GLANDS SHOWN THANKS TO INFRARED MEIBOGRAPHY WITHOUT REQUIRING ANY INPUT FROM THE USER. THE IMAGES ARE THEN AUTOMATICALLY CLASSIFIED.

HOW DOES IT WORK

System analyses automatically the images made through a sensitive infrared camera (NIR) to locate in a guided way:

- An exam valid both for the upper and the lower eyelid,
- Automatic percentage of the extension of meibomian glands in the chosen area, taken by the operator,
- Automatic percentage of the loss area of meibomian glands.

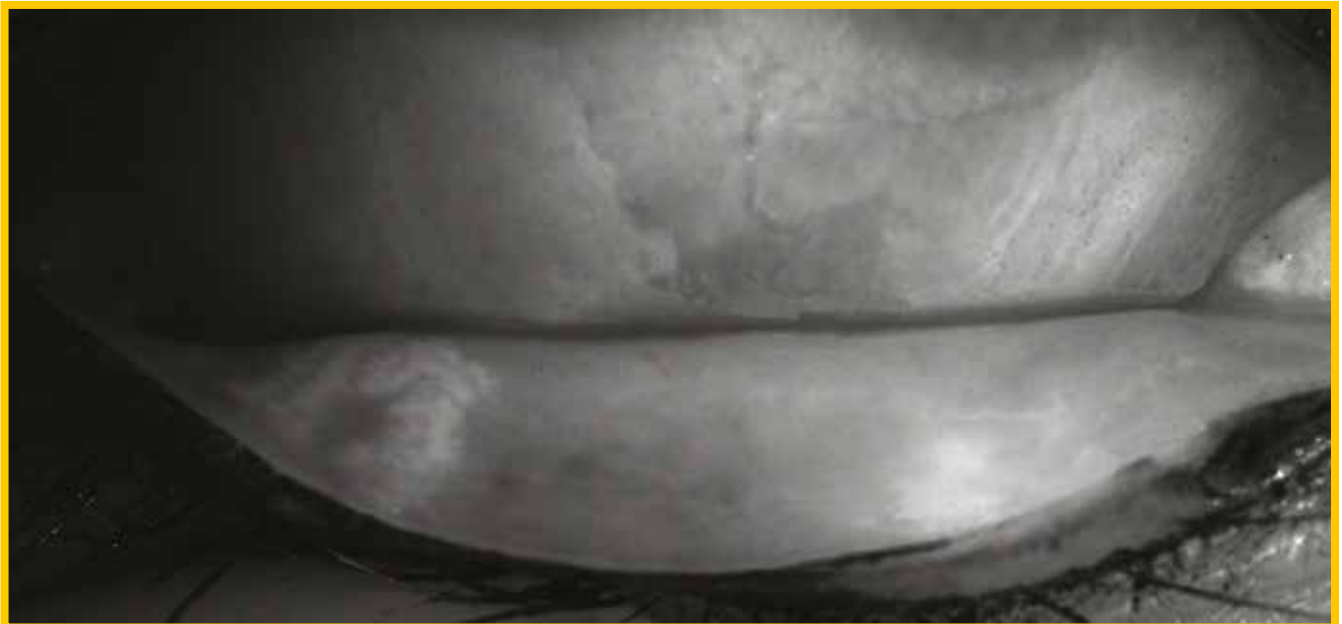If you prefer, instead of the automation it is possible to classify the exam done in degrees according to three different related grading scales.

Meibomian gland dysfunction, or MGD, is one of the most common causes of an abnormal tear film lipid layer and evaporative dry eye, with numerous risk factors reported. Its prevalence varies among countries from 20% to 60%, with one of the highest rates in Japan. It is characterized by terminal duct inspissation, truncation, obstruction and gland dropout, and/or qualitative and quantitative changes in the secretion of the glands.

Meibography - the imaging of the meibomian glands - is now a quick, comfortable point-of-care test that is becoming popular in practices that have made the diagnosis and treatment of ocular surface disease a priority.

Meibography is the only clinically in vivo and noninvasive technique to visualize the morphology of the meibomian glands.

VERY AFFECTED MGD PATIENT



MEIBOGRAPHY IMAGES

The importance of meibography in educating patients and encouraging compliance cannot be overstated. A picture is truly worth a thousand words. When you tell a patient that he has advanced MGD and paint a verbal picture of his future if it is left untreated, he will usually listen politely and then disregard your little speech as so much white noise.

But show him an image of his own glands, and his reaction is completely different. Of course, the doctor must first give him a point of reference; the Sbm Sistemi provide laminated photos that we keep in each exam lane, illustrating normal glands, moderately advanced MGD and severe MGD.

MEIBOGRAPHY

idra



O.s.a.



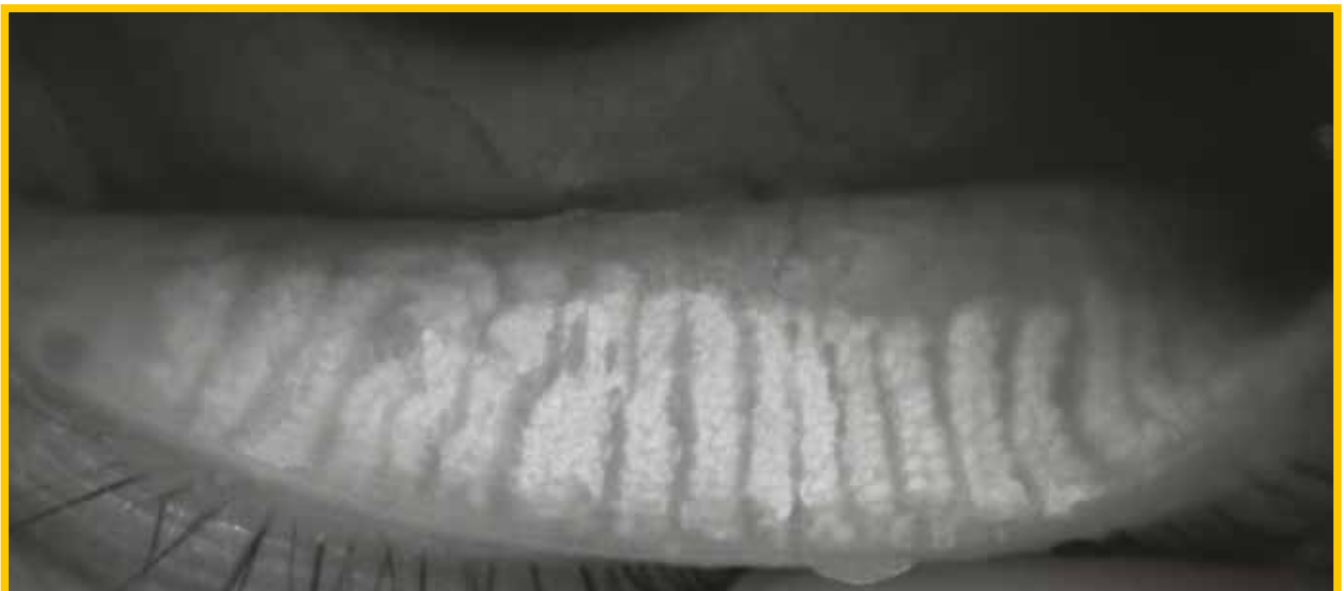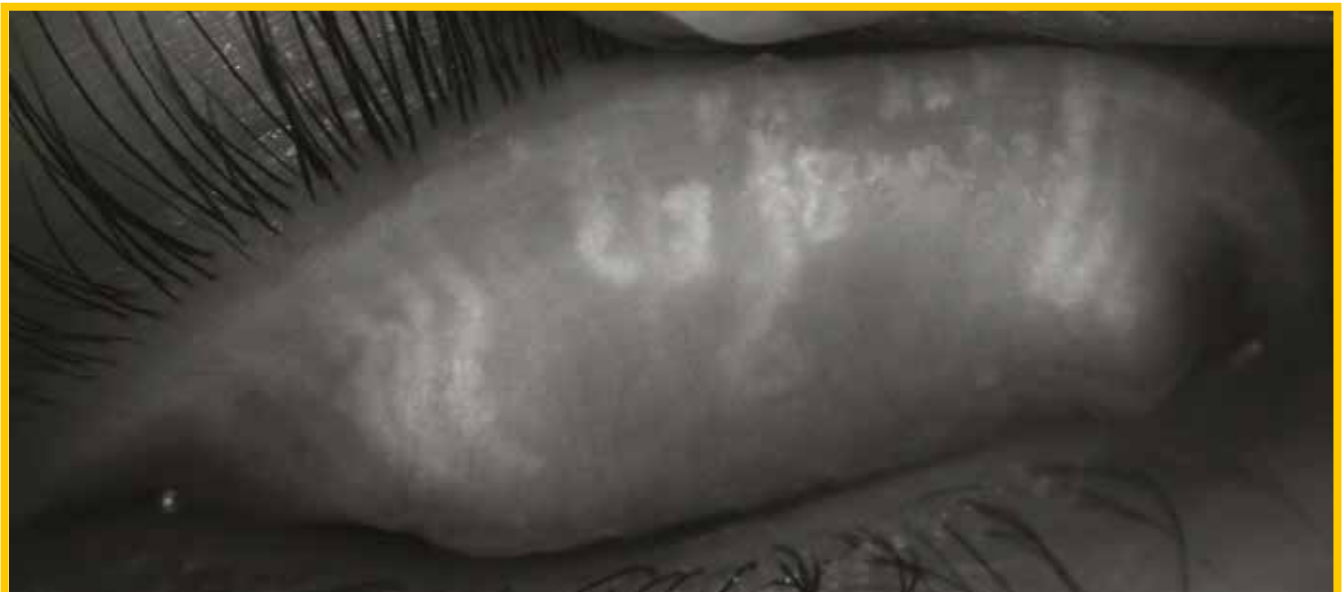Meibomian gland dysfunction (MGD) is characterised by chronic, diffuse abnormalities of the meibomian glands and altered secretion and chemical composition of meibum. MGD leads to increased tear evaporation, increased tear osmolarity and an increased susceptibility to ocular surface inflammation, epithelial damage and discomfort. MGD is the leading cause of dry eye disease and affects

Most of the population Blepharitis is a common eyelid condition that can lead to symptoms ranging from burning, itching, flaking, eyelid discharge, eyelid redness, and the occurrence of frequent "pink eye" like flare ups.

To prescribe treatment therapies such as IPL, different evaluations should be performed relating meibomian glands. SBM Sistemi tools allow an accurate comprehension of the ocular surface and especially the glands.

The acquired image is processed and transformed into 3D picture. Using scientific algorithms it is possible to admire it and demonstrate to the patient the absent parts and their thickness.

It will therefore be easier for professionals in the sector to recommend treatment even if more expensive. It will also be possible to evaluate the efficacy of periocular intense pulsed light therapy combined with meibomian gland.



EXPECTED
RELEASE
DECEMBER
2018

MEIBOGRAPHY 3D

idra



O.S.A.
PLUS



THE REVOLUTIONARY INTRODUCTION OF 3D MEIBOMIAN GLAND IMAGING PROVIDES YOU THE CLINICIAN WITH TWO CLEAR ADVANTAGES. FIRSTLY, IT ENABLES YOU TO CONFIRM THE PRESENCE OF ABNORMAL GLANDS VS. THAT OF A HEALTHY INDIVIDUAL IN A 3D FORMAT AND SECONDLY, IT PROVIDES A CLEAR IMAGE TO SHARE WITH THE PATIENT TO HELP EXPLAIN THE POTENTIAL CAUSE OF THEIR DISCOMFORT. ULTIMATELY THIS NEW IMAGING SYSTEM PROVIDES STRONG EVIDENCE TO SUPPORT YOUR CHOICE OF THERAPY FOR YOUR PATIENT (FOR EXAMPLE IPL TREATMENT) AND HELP THE PATIENT UNDERSTAND WHY THAT THERAPY IS BEING RECOMMENDED.



AN OUTSTANDING DIAGNOSTIC EVALUATION IS NEEDED TO DEMONSTRATE TO THE PATIENT THE EFFECTIVENESS OF THE IPL TREATMENT.

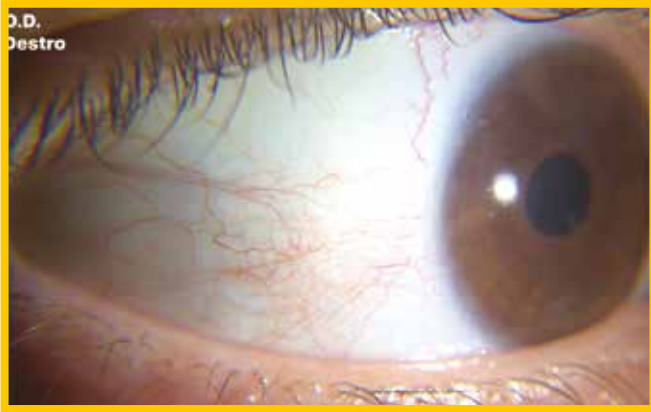Advantages for the Doctor:

- Ability to view the presence of abnormal gland structures in a high resolution 3D image
- Be able to compare and contrast a normal patient gland profile with that of your MGD patient
- The option to visualise these problem areas in high definition vs. that of a less clear 2 dimensional image
- The ability to potentially pin point the areas of gland abnormality in detail
- Evidence that supports your diagnosis in the case of evaporative dry eye disease
- Provides you with much more compelling evidence to help the patient visualise what is happening to them
- Provides the reassurance that MGD is a contributory factor and key to your diagnosis of evaporative dry eye disease
- Clearly show the symptomatic dry eye sufferer a comparison of their abnormal glands vs that of a normal healthy patient
- Help to explain and confirm the reasons for your choice of MGD therapy (including IPL)

Benefits for the patient:

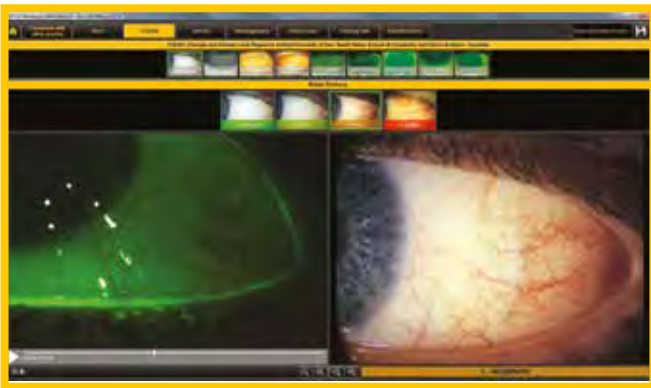- For the first time a 3D image can help them understand the structure of the eye lid and how their Glands are different from a healthy individual
- See for themselves, with the Doctors explanation, why they are getting eye discomfort and fluctuating vision
- Help them understand why you are recommending a particular therapy
- Peace of mind that their clinician is using the very latest techniques make the correct diagnosis of their eye problem and appropriate treatment.

OTHER POSSIBLE EXAMINATIONS



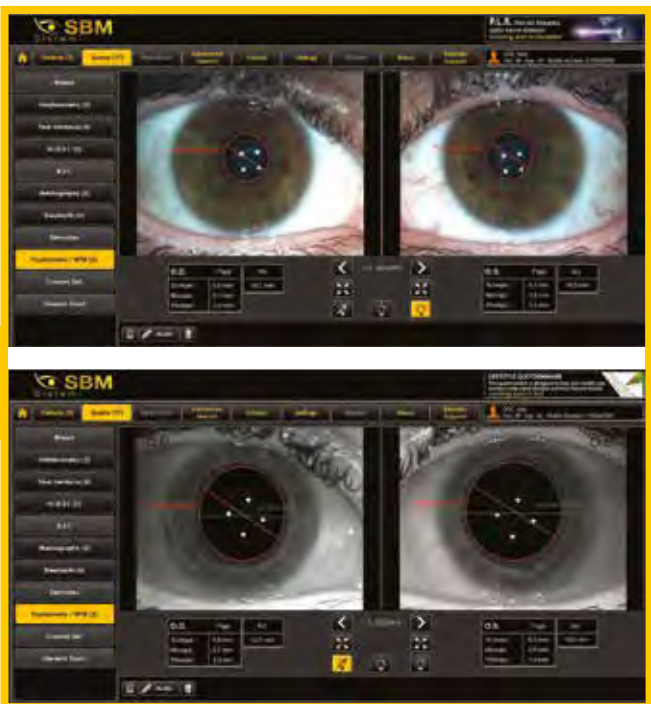
BULBAR REDNESS CLASSIFICATION

Detected the fluidity of the blood vessels of the conjunctiva, evaluating the degree of redness, it will be possible to compare the classification sheets of the degree of redness of bulbar and limbal.



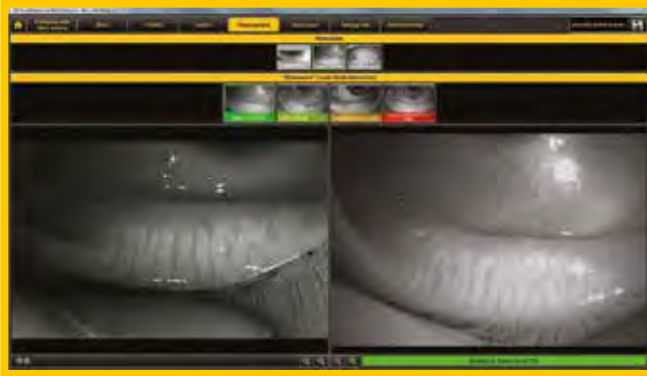COMPARISON WITH THE MAIN INTERNATIONAL GRADING SCALE

EFRON - CCLRU - JENVIS - GLAUCOMA - FERNING TEST - MEIBOGRAPHY



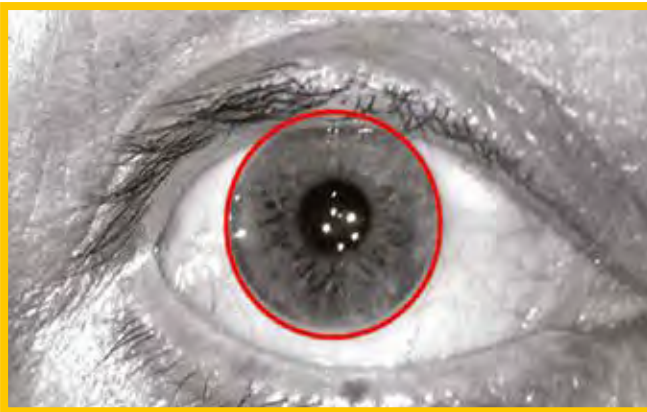
THE MEASUREMENT OF PUPIL DIAMETER

The measurement of pupil diameter has become increasingly important in the field of refractive surgery. Larger scotopic pupil sizes may be partially responsible for the occurrence of postoperative symptoms such as halos, glare, and monocular diplopia.^{1,2} Refractive surgeons also need an accurate scotopic pupil measurement to determine appropriate treatment zones for excimer laser, corneal, and intraocular surgery.



AN ASSESSMENT OF GRADING SCALES FOR MEIBOGRAPHY IMAGES

The evaluation of the meibomian gland dysfunction appears to be of increasing interest in research and clinical practice. Consequently the evaluation of meibomian glands morphology using meibography is of high interest for both, researchers and clinicians.



WHITE TO WHITE MEASUREMENT


Evaluation of corneal diameter from limbus to limbus (white-to-white distance, WTW).

CYLINDRICAL DANDRUFF AND BLEPHARITIS

idra



O.s.o.



The human skin surface is known to house millions of bacteria, though some people have more than the average number. Blepharitis is an inflammation caused by some bacteria that lie at the base of eyelashes. They produce dandruff-like flakes in the skin, which lead to infection and inflammation. Problems with the meibomian oil glands (meibomianitis) in the eyelids can also cause blepharitis. The development of inflammation is also associated with risk factors such as dandruff, dry eyes, acne rosacea, or bacteria. This is a common eye disorder affecting all age groups.

The eye must be evaluated using a specialized tools such as a magnifying tool like the SBM Device. This tool checks for inflammation in the eye and the existence of bacteria/fungi/viruses. If signs of infection are found during close monitoring, the ophthalmologist wipes the eye and collects any fluid oozing from the eyes as sample. This sample is tested under a microscope. Comprehensive Eye Examinations.

BLEPHARITIS AND CYLINDRICAL DANDRUFF

This test helps in detection of blepharitis, which can be performed on the outer surface of the eyeball and eyelids. This process includes:

- Analyzing the patient history that could contribute to blepharitis.
- Extrinsic detection of the eye structure, skin texture, and appearance of eyelashes.
- Examining the openings of the meibomian gland, base of the eyelashes, and eyelid margins using a bright light.
- Checking for abnormalities by evaluating the quantity and quality of tears.

The type of blepharitis can be determined based on the appearance of the eyelid edges. If the symptoms frequently exhibited by the patients are mild sticking eyelids, thickened lid margins, and missing/misdirected eyelashes, then the type of blepharitis is said to be Staphylococcal. If the patients show mild redness of the eyelids or scales around the base of eyelashes, then it is Seborrheic blepharitis.

When the patient is found with blockage of the oil glands in the eyelids, poor quality of tears, and redness of the lining of the eyelids, the type is Meibomian blepharitis. If a hard, matted crust is formed on the eyelashes, and while removing these some small sores are formed on the eyelashes that ooze and bleed, it is called Ulcerative blepharitis. In this case, patients may experience distortion of the front edges of the eyelids, loss of eyelash, and chronic tearing. In severe conditions, the transparent outer portion of the eye that covers the eyeball (cornea) is inflamed.

WHAT IS DEMODEX BREVIS?

Demodex brevis is a kind of mite found on humans. Like its counterpart Demodex folliculorum, brevis is naturally occurring. D. brevis is so small that you can't see the mites with a naked eye.

The average mite causes noticeable reactions and problems in people if it exists in large quantity.

Symptoms of D. brevis usually only surface in cases of large infestations. Signs might include:

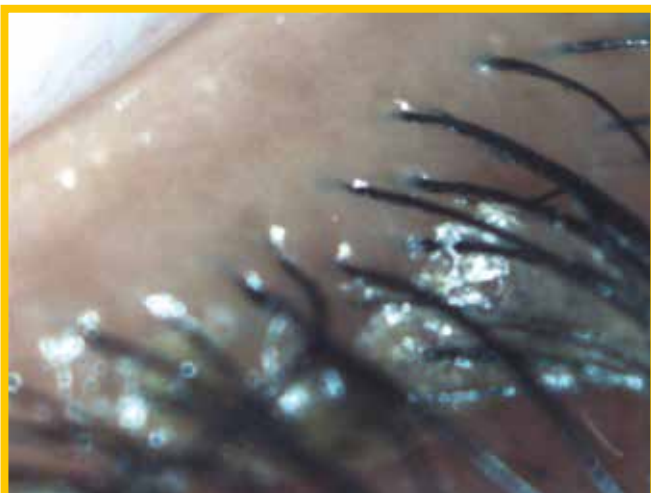- Red skin
- Rough or tough skin
- Scaly or patchy skin

The symptoms of D. brevis are similar to those of D. folliculorum. The key difference is location.

While folliculorum tend to stay on the face, D. brevis can distribute all over the body. The chest and neck are common areas of D. brevis infestation, so you might notice more symptoms there if you have it.

Once in the skin, D. brevis feed off sebum in the oil glands. These glands are attached to hair follicles underneath the skin's surface.

Infestations of D. brevis aren't common in young children, but their numbers naturally grow with age. The mites may also be spread between humans.



NEW RESULTS EXAMS

These values have been grouped in a new section in the exam results screen with all these new values.

All values from "Grading scales" were deliberately put together in a single section later providing the ability to filter the values seeing only those of interest (Redness, Staining, ...)



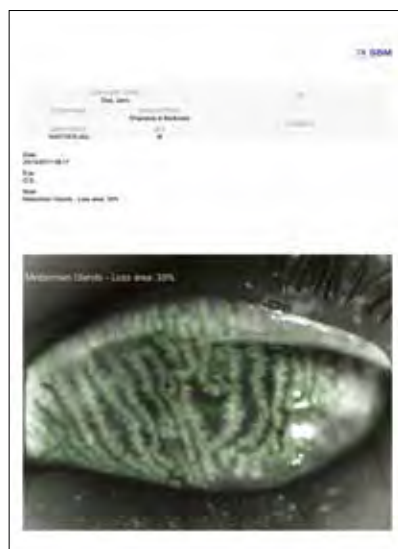DAILY REPORT

It contains all exams values of chosen day



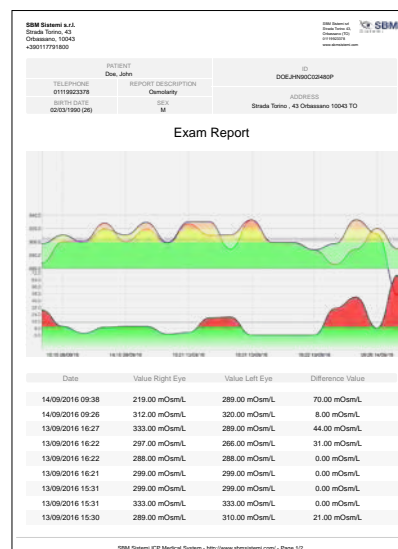
SINGLE VALUE

It includes all the exams done during time of a single test, with the graph representation



MGD

Report with value of a specific exam done, with the relating acquisition



OSMOLARITY, SCHIRMER TEST

It allows to add values of these external tests in the software database



3D MEIBOGRAPHY AUTO	3D MEIBOGRAPHY AUTO	
MEIBOGRAPHY ICP can, in a guided way, detect the length and width of meibomian glands shown thanks to infrared meibography without requiring any input from the user. The images are then automatically classified.		MEIBOGRAPHY ICP can, in a guided way, detect the length and width of meibomian glands shown thanks to infrared meibography without requiring any input from the user. The images are then automatically classified.
AUTO INTERFEROMETRY TEST Lipid Layer		
		INTERFEROMETRY TEST Lipid Layer
AUTONIBUT Evaluation of tear film break-up time breaking map frame by frame	AUTONIBUT Evaluation of tear film break-up time breaking map frame by frame	AUTONIBUT Evaluation of tear film break-up time non invasive and fully automatic.
Produce visual patterns disclosing surface "topography" down to a fraction of a wavelength.	Produce visual patterns disclosing surface "topography" down to a fraction of a wavelength.	
EYE BLINK DETECTION	EYE BLINK DETECTION	
LIFESTYLE QUESTIONNAIRE	LIFESTYLE QUESTIONNAIRE	LIFESTYLE QUESTIONNAIRE
TEAR MENISCUS-HEIGHT Evaluation of the tear film quantity. Up to 5 values	TEAR MENISCUS-HEIGHT Evaluation of the tear film quantity. Up to 5 values	TEAR MENISCUS-HEIGHT Evaluation of the tear film quantity.
FOOT PEDAL		
POSSIBILITY TO MODULATE THE LIGHT INTENSITY		
4 INFRARED LEDS CAN BE MANAGED IN AN INDIFFERENT WAY		
BLEPHARITIS EXAMINATION WITHOUT ADDITIONAL LENS		
PHYSICAL YELLOW FILTER FOR FLUORESCENCE EXAMINATION		
THE FILMS ARE NO LONGER USED		
RED LEDS, IMPLEMENTATION OF NEW PLR EXAMS		
LARGER SURVEY AREA, LARGER CONE, POSSIBILITY OF EXAMINATION WITH GREATER DISTANCE		
15 DEGREES OF INCLINATION FOR BETTER VISUALIZATION OF THE LIPID LAYER		
MAGNETIZED CONES FOR A QUICK REPLACEMENT		
BUT TEST STAINING TEST		BUT TEST STAINING TEST
WHITE TO WHITE MEASUREMENT		WHITE TO WHITE MEASUREMENT
BLEPHARITIS AND CYLINDRICAL DANDRUFF		BLEPHARITIS AND CYLINDRICAL DANDRUFF
PUPILLOMETRY		PUPILLOMETRY
BULBAR REDNESS CLASSIFICATION		BULBAR REDNESS CLASSIFICATION
COMPARISON WITH ALL INTERNATIONAL SCALES SUCH AS		COMPARISON WITH ALL INTERNATIONAL SCALES SUCH AS

ACCESSORY IDRA - OSA

COMPLETE HOLDER



FOOT PEDAL USB USB connection



TABLE



BRIEFCASE

Bags, resistant material to large stresses, have the particularity to be watertight with IP 67 impermeability and the perfect seal for liquids and dust, this is ensured by a rubber seal along the entire closure profile; is also present in all models a balancing valve of the internal and external pressure. Customizations are possible such as bespoke interior, screen prints or stickers.



TABLE HOLDER





ACCESSORY OSA

LENS FOR CYLINDRICAL DANDRUFF IMAGING



I.C.P. OSA FILM



DEALER